

Anatomy, Biomechanics, Imaging, and Management of Ligamentum Teres Injuries¹

TEACHING POINTS

See last page

*Luis Cerezal, MD • Ara Kassarian, MD, FRCPC • Ana Canga, MD
María Carmen Dobado, MD • Juan Antonio Montero, MD, PhD • Eva Llopis, MD • Alejandro Rolón, MD • Luis Pérez-Carro, MD*

The ligamentum teres has traditionally been viewed as an embryonic remnant with no role in the biomechanics or vascularity of adult hips. However, the ligamentum teres is a strong intraarticular ligament that is anatomically and biochemically similar to the anterior cruciate ligament of the knee. It is composed of two bands that originate from the acetabular transverse ligament and the pubic and ischial margins of the acetabular notch. Among other functions, the ligamentum teres is an important stabilizer of the hip, particularly in adduction, flexion, and external rotation. Abnormalities of the ligamentum teres account for 4%–15% of sports-related injuries and should be considered in the differential diagnosis of patients with hip pain. Lesions of the ligamentum teres include partial or complete traumatic tears, degenerative tears, avulsion fractures of the ligament at its insertion into the fovea capitis femoris, and a congenital absence of the ligament. Magnetic resonance arthrography and computed tomographic arthrography are the preferred modalities for precise preoperative diagnosis of ligamentum teres injuries and may be used to rule out other associated intraarticular injuries. Treatment of these lesions is still evolving; at present, treatment of most injuries is limited to arthroscopic débridement.

©RSNA, 2010 • radiographics.rsna.org

Abbreviations: ACL = anterior cruciate ligament, DDH = developmental dysplasia of the hip

RadioGraphics 2010; 30:1637–1651 • Published online 10.1148/rg.306105516 • Content Code: MK

¹From the Department of Radiology, Diagnóstico Médico Cantabria, Calle Castilla 6 Bajo, 39002 Santander, Cantabria, Spain (L.C., A.K.); Departments of Radiology (A.C.) and Orthopedic Surgery (L.P.C.), Valdecilla University Hospital, Santander, Cantabria, Spain; Department of Radiology, Clínica Creu Blanca, Barcelona, Spain (M.C.D); Department of Anatomy, Cantabria University, Santander, Cantabria, Spain (J.A.M.); Department of Radiology, Hospital de la Ribera, Alzira, Valencia, Spain (E.L.); and Department of Radiology, Centro Diagnóstico Rossi, Buenos Aires, Argentina (A.R.). Presented as an education exhibit at the 2009 RSNA Annual Meeting. Received February 10, 2010; revision requested April 6 and received April 26; final version accepted June 25. A.K. is a consultant for Arthrosurface, Inc; all other authors, editors, and reviewers have no relevant relationships to disclose. **Address correspondence to** L.C. (e-mail: lcerezal@gmail.com).

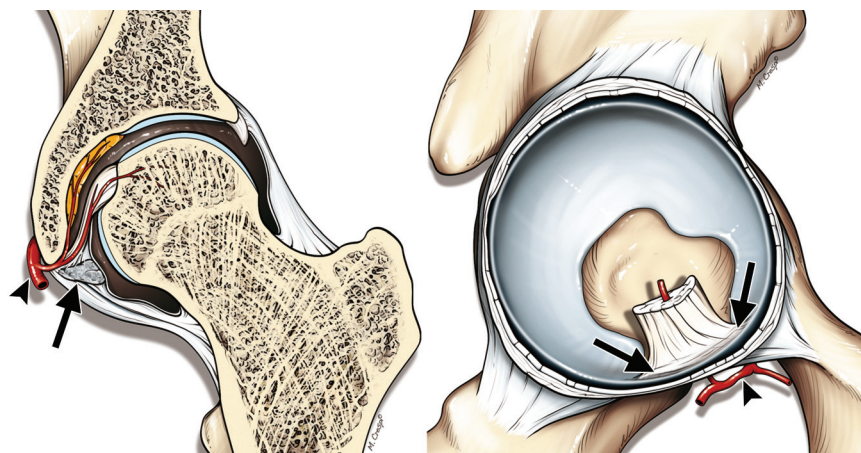


Figure 1. Diagrams show the normal anatomy of the ligamentum teres. The ligamentum teres has a broad origin that blends with the entire transverse ligament of the acetabulum (arrows) and is attached to the ischial and pubic sides of the acetabular notch by two bands. It inserts into the fovea capitis femoris, and its arterial supply is provided by the anterior branch of the posterior division of the obturator artery (arrowhead). Vascular canals extend a short distance from the fovea capitis into the femoral head.

Introduction

To date, reports of lesions of the ligamentum teres in orthopedic and radiologic journals have been limited (1–12). However, due to the increasing use of hip arthroscopy, recognition of lesions of the ligamentum teres has increased substantially, as has interest in the role of the ligamentum teres in hip pain and stability. The prevalence of tears of the ligamentum teres that are discovered at hip arthroscopy is 4%–15% (1,2,4). In addition, lesions of the ligamentum teres have been cited as the third most common cause of hip pain among athletes (4).

With current modalities such as multidetector computed tomography (CT) and high-field magnetic resonance (MR) imaging (1.5–3.0 T), as well as improvements in MR imaging coils and an increasing use of CT and MR arthrography, intraarticular structures of the hip (including the ligamentum teres) are well visualized (9,13–17).

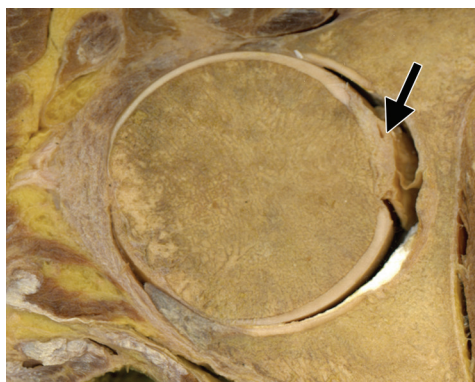
In this article, the anatomy and biomechanics of the ligamentum teres and mechanisms and patterns of injury are discussed, as are clinical findings and imaging appearances, arthroscopic correlation, and treatment of ligamentum teres injuries.

Anatomy

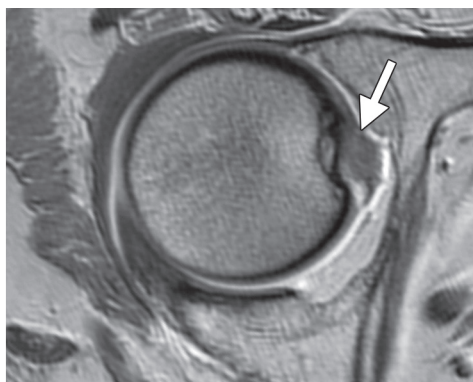
Near the end of the 2nd month of intrauterine life, the ligamentum teres develops from rudimentary mesenchymal cells in the acetabular fossa. During the last 4 months of intrauterine life, the composition of the ligament alters from a predominantly cellular structure to mature fibrous tissue (1).

The ligamentum teres predominantly arises from the transverse acetabular ligament along the inferior margin of the acetabulum. It is attached to the periosteum by two bands (fascicles), which are located along the ischial and pubic margins of the acetabular notch (Fig 1) (1,2,9). Demange et al (18) described three bundles of the ligamen-

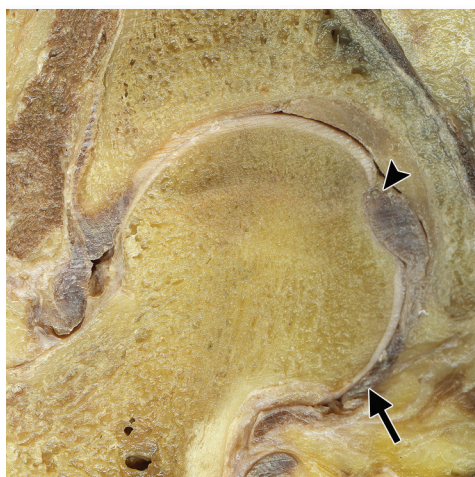
**Teaching
Point**



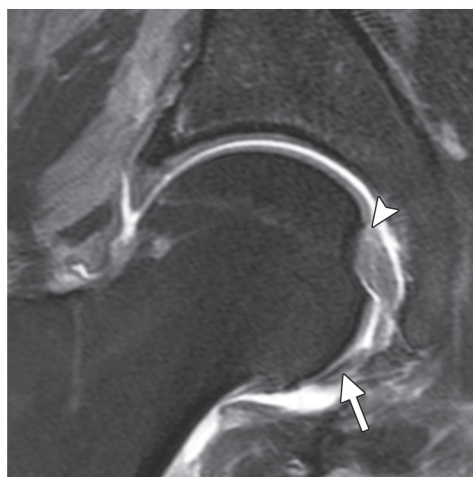2a.



2b.



3a.



3b.

Figures 2, 3. Normal anatomy of the ligamentum teres. (2) Photograph of an axial cadaveric section (a) and corresponding T1-weighted MR arthrogram (b) show the insertion of the ligamentum teres into the anterosuperior aspect of the fovea capitis femoris (arrow). (3) Photograph of a coronal oblique cadaveric section (a) and T1-weighted fat-suppressed MR arthrogram (b) show the entire length of the ligamentum teres, from its origin in the transverse acetabular ligament (arrow) to its insertion into the fovea capitis femoris (arrowhead).

tum teres: anterior, posterior, and medial; the posterior bundle is the strongest, and the medial bundle is the thinnest. To our knowledge, no experimental data supporting the relative strengths of these bundles have been published. Along its acetabular aspect, the ligamentum teres has a flat and somewhat pyramidal shape that gently

transitions into a round or ovoid shape near the femoral attachment and terminates in a tightly bound, round or slightly ovoid ligament, where it attaches to the fovea capitis (Figs 2–6). Its overall length typically is 30–35 mm (1,2,19).

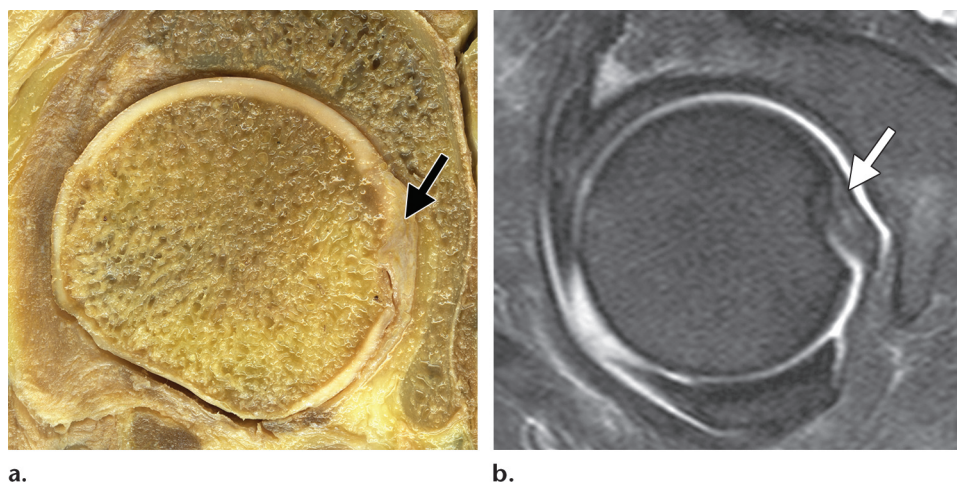


Figure 4. Normal anatomy of the ligamentum teres. Photograph of a coronal oblique cadaveric section (**a**) and corresponding proton-density fat-suppressed MR arthrogram (**b**) show the broad insertion of the ligamentum teres into the fovea capitis femoris (arrow).

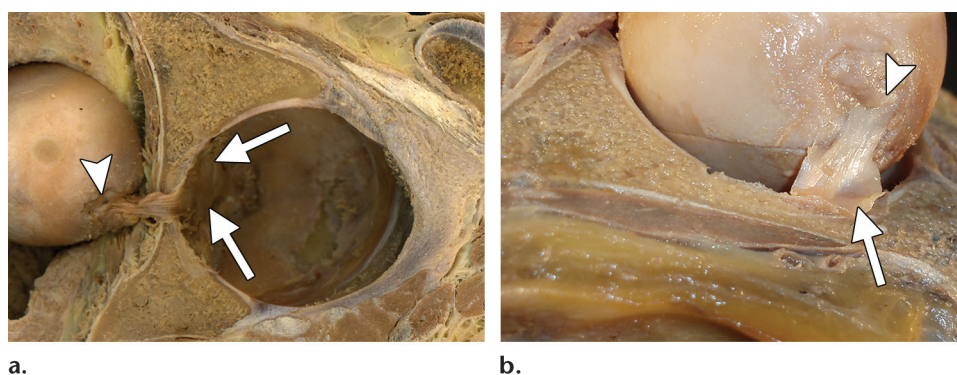


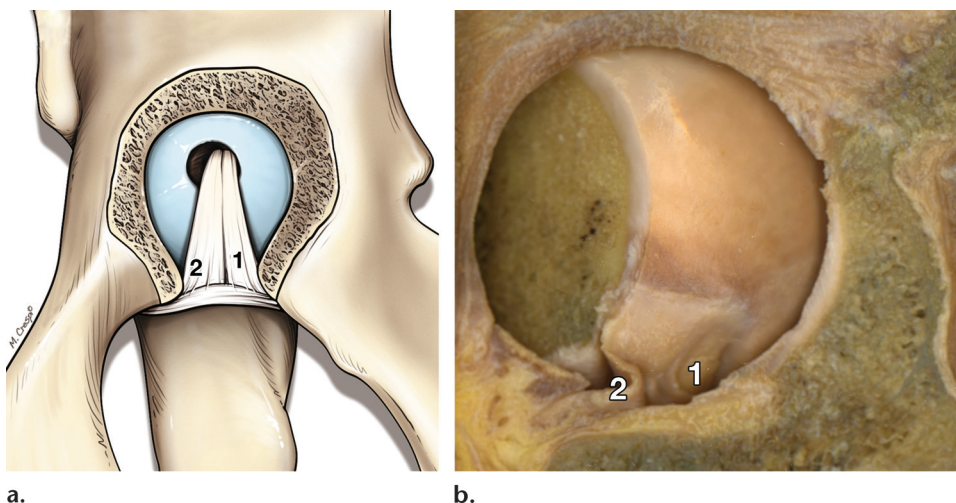
Figure 5. Normal anatomy of the ligamentum teres. Photographs of cadaveric sections show the ligamentum teres along its entire length, from its origin in the acetabulum and transverse acetabular ligament (arrows) to its insertion into the fovea capitis femoris (arrowhead). Note the dislocated femoral head (**a**).

The fovea capitis is a focal depression in the femoral head and typically is located slightly posterior and inferior to the center of the articular surface of the femoral head. No hyaline cartilage overlies the fovea capitis. The fovea is slightly ovoid, with an oblique, superior-to-posteroinferior orientation, a configuration that is thought to help accommodate the fibers of the ligamentum teres when it is tensed (1,2).

The synovial membrane of the ligamentum teres rests over a subsynovial layer of vessels and

adipose tissue. A thick layer of well-organized collagen makes up the deepest layer of tissue that invests the ligamentum teres. The ligament is composed of thick, well-organized, parallel, and slightly undulating or wavy fibers of collagen bundles that are composed of collagen type I, III, and V. These dense fibers are seen at histologic analysis and tend to be slightly less organized and not as regular as those in tendons (1,2,9,20).

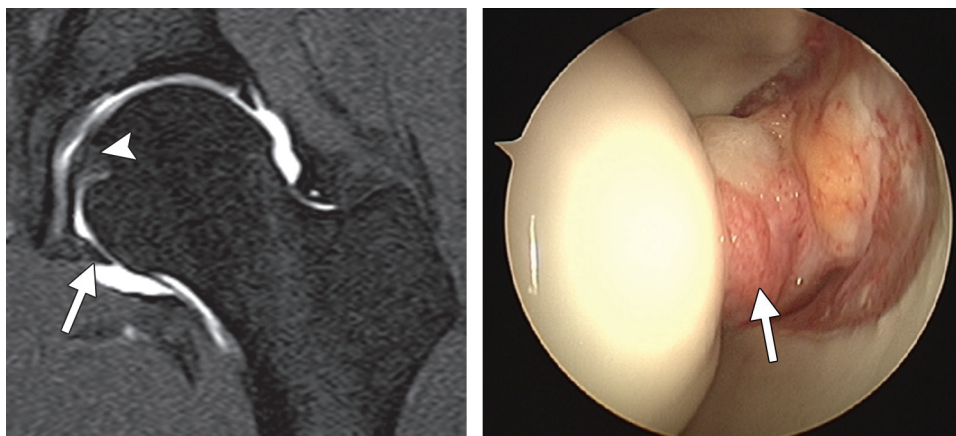
An anterior branch of the posterior division of the obturator artery provides the blood supply to the ligamentum teres. Vascular canals extend from the fovea capitis into the femoral head; how-



a.

b.

Figure 6. Diagram (a) and photograph of a cadaveric section (b) show the normal appearance of the ligamentum teres when the hip joint is opened by removing the floor of the acetabulum from within the pelvis; the ligamentum teres is visible at center. 1 = ischial fascicle, 2 = pubic fascicle.



a.

b.

Figure 7. Normal anatomy of the ligamentum teres. (a) Coronal T1-weighted fat-suppressed MR arthrogram shows the entire length of the ligamentum teres, from the acetabular transverse ligament (arrow) to the fovea capitis femoris (arrowhead). (b) Arthroscopic image shows a normal ligamentum teres (arrow).

ever, because these arteries are not patent in one-third of adults, their contribution to femoral head vascularity varies (1,2,21,22).

At CT and MR imaging, the ligamentum teres has a smooth contour and a relatively homogeneous structure, and at MR imaging it is hypointense with all pulse sequences, although areas of slightly increased signal intensity may be seen near its attachment to the fovea capitis femoris, a finding that may be due to the “magic angle” artifact.

At MR imaging and MR arthrography, the ligament is well depicted on all imaging planes except sagittal because of partial-volume averaging in this plane, and the ligament may appear striated and have two to three bundles and a slightly bi-lobed appearance (Figs 7–9) (2,9,13,14).

Teaching
Point

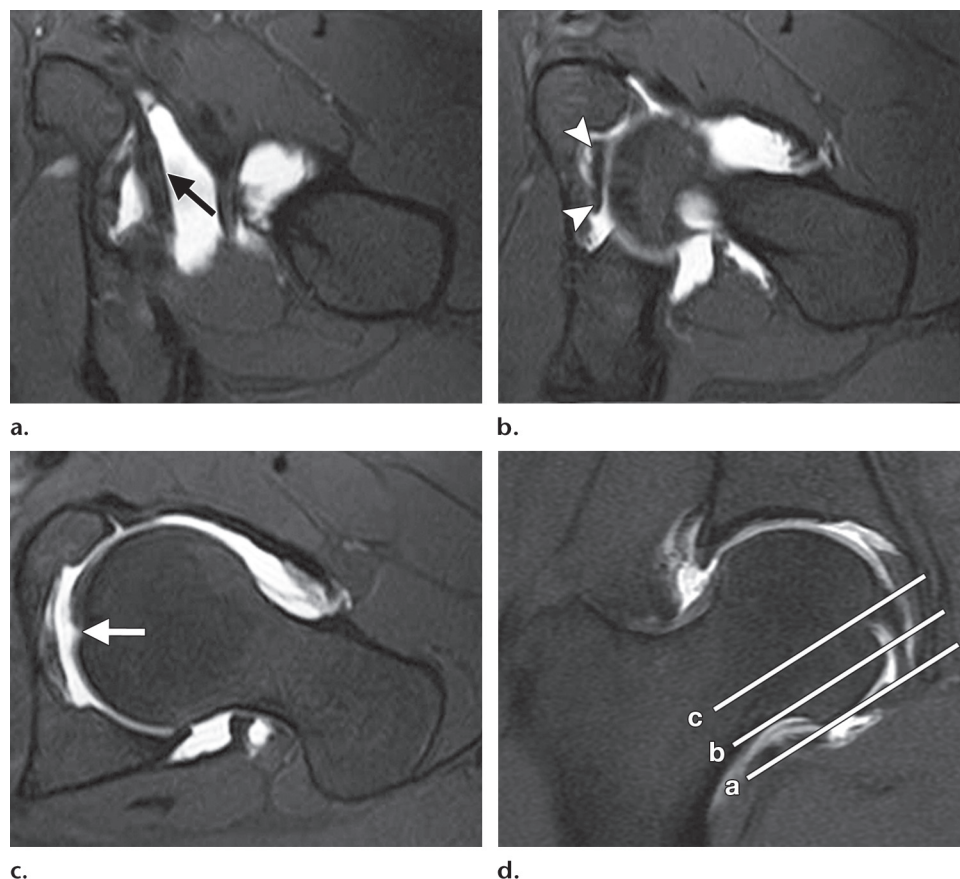


Figure 8. Normal anatomy of the ligamentum teres. (**a–c**) Consecutive oblique axial T1-weighted fat-suppressed MR arthrograms show the acetabular transverse ligament (arrow in **a**), the middle one-third of the ligamentum teres (arrowheads in **b**), and the insertion of the ligamentum teres into the fovea capitis femoris (arrow in **c**). (**d**) Coronal T1-weighted fat-suppressed MR arthrogram shows the levels at which **a–c** were obtained.

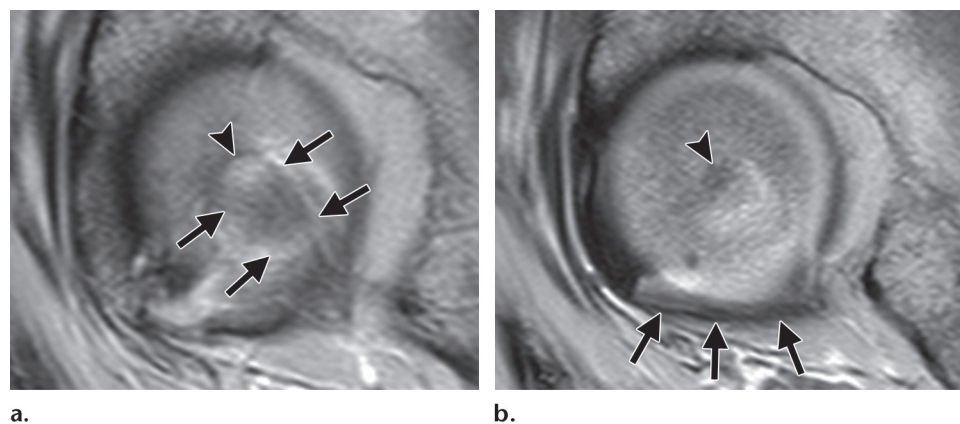


Figure 9. Consecutive sagittal T1-weighted MR arthrograms show the ligamentum teres (arrows in **a**), the fovea capitis femoris (arrowhead), and the acetabular transverse ligament (arrows in **b**).

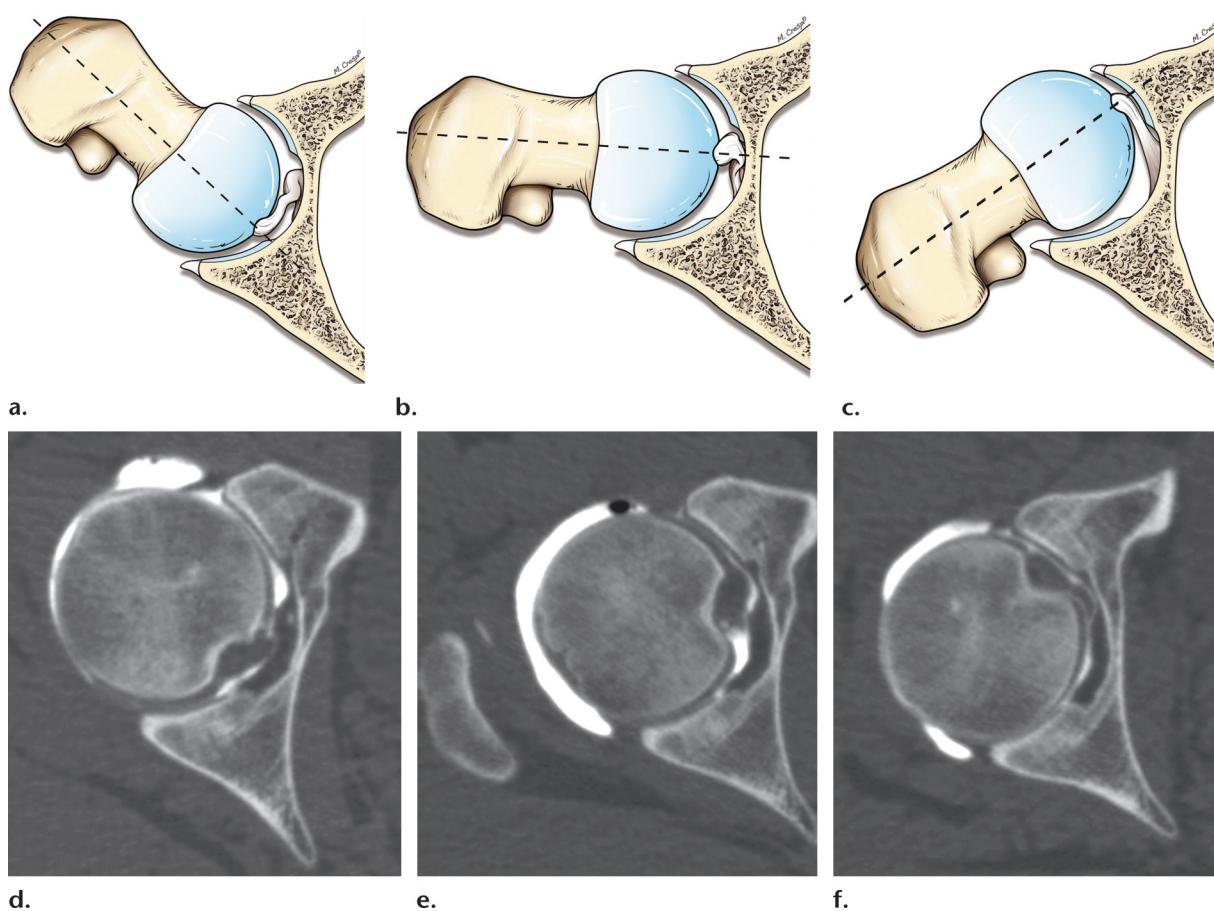


Figure 10. Function of the ligamentum teres. Diagrams (a–c) and dynamic volume CT images (d–f) show the changes in configuration of the ligamentum teres when the hip is rotated. The ligament is slightly lax during internal rotation (a, d) and taut during external rotation (c, f). It is slightly lax when the hip is neutral (b, e).

Function

Although the exact function of the ligamentum teres is not clear, several theories have been proposed. **First, the ligamentum teres may be to the hip what the anterior cruciate ligament (ACL) is to the knee: a strong intrinsic stabilizer that resists joint subluxation forces (2,19,23).** In animal models, when the ligamentum teres is severed, the rate of hip dislocation increases (24). It has not been proved if a torn ligamentum teres increases the risk for dislocation in humans. It has been theorized that the ligamentum teres plays a mechanical role in hip stabilization because it is most taut when the hip is in its least stable positions (flexion, adduction, and external rotation) (1,2). It typically is more lax in hip abduction and internal rotation (Fig 10). However, scientific evidence in humans is lacking.

Patients with a torn ligamentum teres develop subtle hip instability, which sometimes is referred to as microinstability. Microinstability is aggravated by sporting activities such as running, football, and tennis and leads to damage to the labrum and cartilage, a characteristic that explains the high rate of association between a torn ligamentum teres, labral tears, and cartilage lesions (8,25). It has been theorized that among those who participate in high-impact sports, recurrent hip subluxation (ligamentum teres-deficient hips are susceptible to this type of injury) is the cause of femoral head osteonecrosis. However, there is no scientific evidence to date that indicates whether a torn ligamentum teres is the cause of hip subluxation or merely an effect.

Second, the ligamentum teres may play a role in nociception and coordination of movement. The ligamentum teres has type IVa receptors and transmits afferent somatosensory signals, which have been identified in both normal and dysplastic hips (26). Leunig et al (27) postulated that the ligament may play a role in proprioception in patients with arthropathy and that it acts as a stabilizer to prevent excessive movement.

Third, the ligamentum teres provides blood supply to the developing femoral head, a function that typically is negligible in adults (2). Finally, Gray and Villar (6) theorized that the ligamentum teres helps distribute synovial fluid within the hip joint by way of the “windshield wiper” effect.

Classification of Injuries

Gray and Villar (6) classified tears of the ligamentum teres into three types on the basis of arthroscopic findings: complete rupture (type I), partial rupture (type II), and degenerative ligament tear (type III).

Complete ligamentous tear (type I) typically occurs in those with a history of traumatic or operative joint disruption. These patients also have a high incidence of other intraarticular conditions such as chondral lesions and labral tears (4,8,25).

Partial ligamentous tear (type II) typically occurs in patients with a long history of symptoms and chronic, vague hip pain, typically in the groin or thigh; few other findings are present. Patients with partial ligamentous tear typically have undergone previous imaging of the hip (and possibly surgery) with negative results. The diagnosis is established at arthroscopy, which depicts minor associated intraarticular conditions in patients who participate in sports (6).

Degenerative tear (type III) typically is associated with osteoarthritis (9,11). Around 60% of patients have a joint condition such as acetabular dysplasia, Perthes disease, and slipped capital femoral epiphysis, as well as radiologic evidence of osteoarthritis.

Appearance in Other Conditions

The ligamentum teres may be thickened, hypertrophied, or elongated in patients with developmental dysplasia of the hip (DDH), in which repeated or constant traction on the attachment of the ligament centrally leads to hypertrophy of the transverse acetabular ligament, which in turn further decreases the size of the acetabular fossa and prevents reduction of the hip (28). To recover adequate clearance, open reduction of DDH often is performed, during which the ligamentum teres and the pulvinar are removed.

Newborns with DDH tend to have higher amounts than normal of type III and type I collagen in the ligamentum teres and umbilical cord, a finding that has been theorized to cause DDH. However, the increased amounts of these types of collagen may indicate adaptive changes to prevent hip dislocation. Preservation and transfer (rather than excision) of the ligamentum teres have been recommended on the basis of animal models of DDH, but to date, published human studies do not corroborate this strategy (29).

In Perthes disease, thickening of the arterial wall, which obliterates the vessel lumen of the ligamentum teres arteries, and associated edema and perivascular infiltration are seen. As the ligament becomes swollen, it is believed that it contributes to subluxation of the hip, which carries a poorer prognosis.

In osteonecrosis of the femoral head, adaptive overgrowth of the ligamentum teres may be seen, with hypertrophy of the ligament and increased numbers of well-organized collagen fibers. Altered hip biomechanics and biologic stimuli may lead to a release of growth factors, which results in overgrowth of the ligamentum teres, a theory that has not been proved (2). In ankylosing spondylitis and diffuse idiopathic skeletal hyperostosis, ossification of the ligamentum teres may be seen, a finding that may result in superolateral subluxation of the femoral head and associated arthrosis (30,31).

Similarities Between the Ligamentum Teres and the ACL

The ligamentum teres shares some common features with the ACL (2). Both ligaments are strong, bundled, and intraarticular, as opposed to most other ligaments in the body, which tend to be extraarticular and represent thickening of the joint capsule. At histopathologic analysis, the ligamentum teres and the ACL have similar collagen distribution and fibroblast characteristics, and both contain nerve endings. They also have similar biomechanical properties and ultimate load-to-failure ratios. Clinically, both have poor healing capacity, and they may become ossified in certain enthesopathies. However, the ligamentum teres has better healing capacity than the ACL (2).

Mechanisms of Injury and Associated Lesions

Although a torn ligamentum teres typically is associated with hip dislocation, partial or complete tears may occur in the setting of other joint stresses such as a flexion-adduction stress, which occurs when a patient falls on the ipsilateral knee with the hip flexed, or a sudden twisting injury (usually external rotation) of the hip (1,2,4).

Teaching
Point

Although tears of the ligamentum teres are thought to occur with exaggerated adduction and external rotation of the hip, the most common history related by patients is a hip abduction injury. De Lee (32) described a proposed mechanism in which anterior hip dislocation causes a tear of the ligamentum teres. According to this theory, the posterior aspect of the femoral neck is in contact with the acetabular rim, which raises the femoral head and displaces it anteriorly. It also stretches the ligamentum teres, which becomes impacted and interposed between the femur and the anterior acetabular rim, causing the ligament to tear. An associated anterior capsular tear also typically results from this mechanism.

Delcamp et al (5) also proposed hip abduction as a cause of ligamentum teres tears, but without hip dislocation. According to this theory, anterior hip subluxation occurs without capsular disruption, which causes the ligament to stretch and eventually fail. This mechanism also has been proposed in patients with hyperabduction and transient hip dislocation with spontaneous reduction (5,33). A similar situation may occur in children, although it more commonly results in osteochondral avulsion of the femoral head (rather than ligamentous tear). This mechanism is analogous to that of ACL tears: Among children, an avulsion fracture of the tibial eminence may be present instead of an ACL tear (3).

Partial tears of the ligamentum teres also are thought to occur when the hip is in hyperabduction with associated excessive external or internal rotation. Given these proposed mechanisms of injury, tears of the ligamentum teres may occur in high-impact sports (eg, American football and hockey) or those that require extreme ranges of motion (eg, ballet and martial arts) (1,2,8). Surgical dislocation of the hip, which may be employed for open treatment of femoroacetabular impingement, also may necessitate disruption of the ligamentum teres to allow disarticulation of the hip and provide adequate access to the acetabular rim.

Cases of acute ligamentous injuries that occur during the activities of daily living have been reported, but they solely involved femoral avulsion fractures of the ligament (12). Congenital absence of the ligamentum teres also has been reported in patients with developmental dysplasia of the hip or diastrophic dysplasia; however, we are not aware of a study on the incidence or significance of congenital absence of the ligamentum teres in normal hips (34). In cases of congenital absence, the fovea capitis femoris may be hypoplastic.

Clinical Diagnosis of Injuries

Physical examination of the hip is challenging. Although there are techniques that are sensitive

for the detection of intraarticular conditions, no specific test exists for the detection of tears of the ligamentum teres (1,2,4,35). Thus, a detailed clinical history, careful analysis of the mechanism of injury (eg, a twisting injury, fall on flexed knee, or hyperabduction), and a high level of suspicion are critical. Regardless, a clinical diagnosis of a tear of the ligamentum teres remains challenging.

Although patients may describe hip and groin pain, locking, catching, and giving way, all of these symptoms are nonspecific and may be encountered in the setting of other intraarticular conditions. For instance, patients with degenerative joint disease may describe a long history of buttock, thigh, or groin pain that is aggravated by walking and decreased abduction and hip rotation (9).

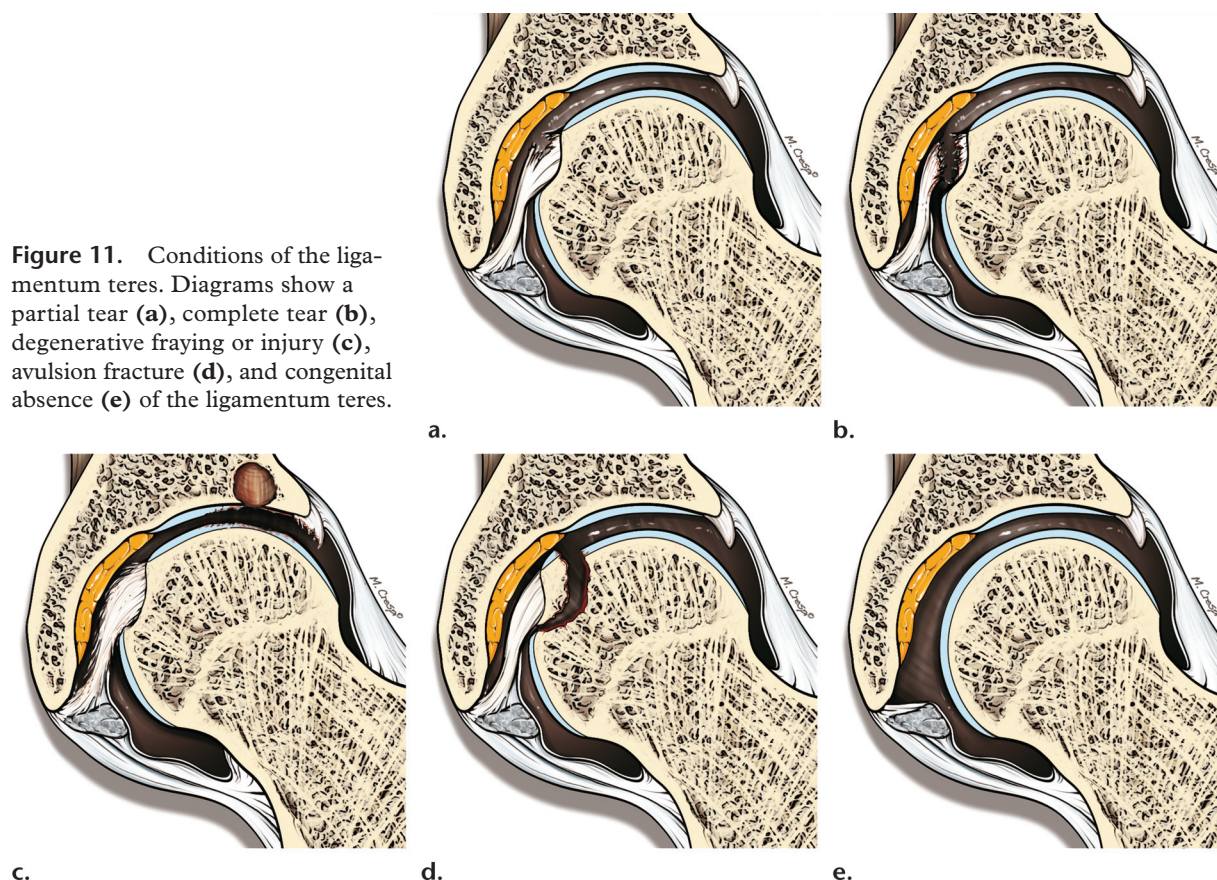
At physical examination, a reduced or painful range of motion in extension, flexion, or internal rotation may be present, as well as decreased extension, painful straight leg raise, and locking of the joint, which is more common in degenerative tears of the ligamentum teres than in other conditions. Unfortunately, similar to the symptoms of ligamentum teres tears, these features are nonspecific and may be seen with other intraarticular hip conditions. A complete examination should be performed including the log roll, resisted straight leg raise, and McCarthy tests (flex both hips and passively extend the symptomatic hip in internal rotation followed by external rotation) (1,2,4). It is important to note that disabling symptoms may not be present, particularly in athletes.

CT and MR Imaging Features

Although nonarthrographic MR imaging is adequate for the evaluation of most joints, MR arthrography and CT arthrography provide superior assessment of intraarticular lesions of the hip (9,13–17). This superiority is due to a number of factors: (*a*) Because the hip is a deeply seated joint, MR imaging coils cannot be placed as close to the center of the joint as is possible with peripheral joints such as the knee; (*b*) no dedicated hip coils are currently available; and (*c*) because the hip is a tight joint, its intraarticular structures are very closely opposed, which can make it difficult to accurately assess their margins. The advantage of MR and CT arthrography is that as the joint distends, contrast material is able to flow between the individual structures and outline their margins and surfaces, allowing depiction of subtle lesions. MR and CT arthrography with the leg in traction are technically feasible and safe, and they improve visualization of the femoral and acetabular cartilage surfaces (36).

At MR imaging, the ligamentum teres is best visualized on coronal, axial, and axial oblique

Figure 11. Conditions of the ligamentum teres. Diagrams show a partial tear (a), complete tear (b), degenerative fraying or injury (c), avulsion fracture (d), and congenital absence (e) of the ligamentum teres.



images. A normal ligamentum teres has a smooth contour and has homogeneous low signal intensity with all pulse sequences (9,13–17). The entire course of the ligamentum teres is visible on coronal MR, CT arthrographic, and MR arthrographic images, and it has a cordlike appearance with mild expansion in the vicinity of its insertion to the femoral head. On axial or axial oblique images, the inferior two-thirds of the ligamentum teres have a 2–4-mm thick flattened bandlike appearance and smooth margins, and a slightly lobulated appearance may be seen. This appearance gently transitions into a more round or oval shape nearer to the femoral attachment and terminates in a tightly bound, rounded or slightly ovoid ligament at the attachment to the fovea capitis.

Abnormalities of the ligament that may be seen at MR arthrography include hypertrophy, fraying, discontinuity, and increased signal intensity (Fig 11) (9,13). At conventional MR imaging, edema may be seen adjacent to the ligament in the acetabular (cotyloid) fossa. However, such edema may be difficult to appreciate at MR arthrography because of the confounding effects of gadolinium

contrast material on intraarticular structures. **Because partial and complete tears of the ligamentum teres are most common near the fovea capitis femoris, close attention should be paid to this region when evaluating MR, MR arthrographic, and CT arthrographic images of the hip (8).**

Accurate assessment of ligamentum teres tears requires the combined use of coronal and axial or axial oblique imaging planes. The axial oblique plane is particularly useful for differentiating grades of ligamentum teres injuries, particularly because individual coronal images may depict segments of the ligamentum teres fibers. Use of the axial oblique plane increases the specificity of MR, CT arthrography, and MR arthrography for differentiation of partial and complete ligamentum teres tears because the ligament is seen in cross section.

In acute ligamentum teres tears, primary signs of ligament rupture such as discontinuity of the ligament and a wavy or lax contour are visible at MR imaging, CT arthrography, and MR arthrography. The injured ligamentum teres usually demonstrates increased signal intensity on T2-weighted, fat-suppressed proton-density, or T2*-weighted MR images. An edematous soft-tissue mass may be seen in the region of the torn fibers.

Teaching Point

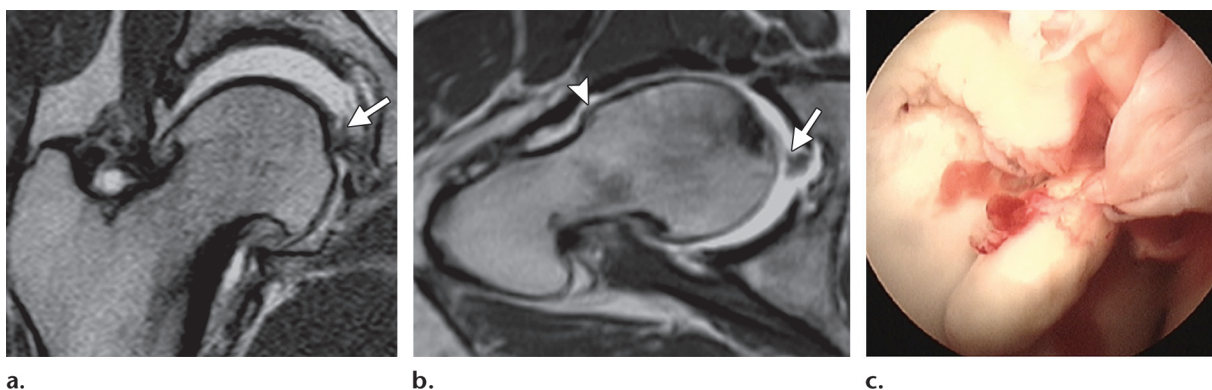


Figure 12. Complete tear of the ligamentum teres. (a, b) Coronal (a) and axial oblique (b) T1-weighted MR arthrograms obtained with the leg in traction show a chronic, complete tear of the ligamentum teres at its foveal attachment (arrow) and severe secondary instability, recognizable by a marked increase in joint space when the leg is in traction. Cam-type femoroacetabular impingement also is seen, with an abnormal protuberance at the femoral head-neck junction (arrowhead in b). (c) Arthroscopic image shows a tear in the ligamentum teres at the foveal attachment.

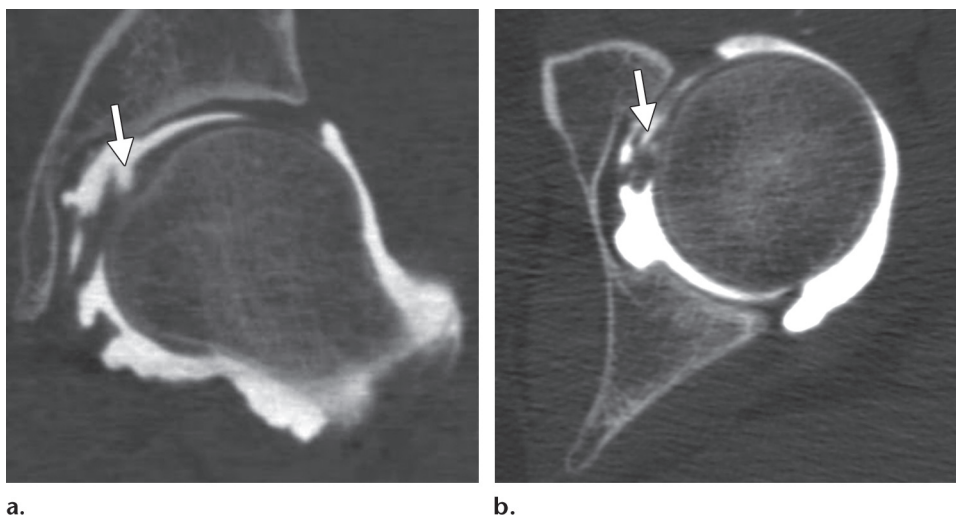


Figure 13. Partial tear of the ligamentum teres in a patient with a history of groin pain, catching, and locking. Coronal (a) and axial (b) CT arthrograms show extension of contrast material into the proximal part of the ligamentum teres and irregularity of the same part of the ligament (arrow), findings indicative of a partial tear.

Widening of the entire ligament with blurring of the ligamentum teres fascicles, a finding due to edema or hemorrhage, is seen in the presence of an interstitial tear. Secondary nonspecific signs of acute ligamentum teres tears include edema in the acetabular fossa, synovitis, and joint effusion.

The diagnostic accuracy of CT arthrography and MR arthrography in particular is far superior to that of MR imaging for evaluation of ligamentum teres tears. This accuracy is particularly important for chronic lesions, which may not demonstrate the secondary signs of rupture that are seen in acute tears. In chronic ligamentum teres tears, a focal loss of continuity and elongation of the ligament, which may already have an irregular or lax contour, may be seen (Fig 12). The

ligamentum teres also may appear abnormally attenuated in patients with chronic tears.

Accurate assessment of partial ligamentous tears is more difficult than that of complete disruption. Partial tears of the ligamentum teres are characterized by abnormal intrasubstance signal intensity and concomitant morphologic alterations such as thickening secondary to scar formation, abnormal attenuation of the ligament, and focal partial loss of continuity (Figs 13, 14). CT arthrography and MR arthrography best delineate morphologic contour alterations and partial fluid-filled defects.

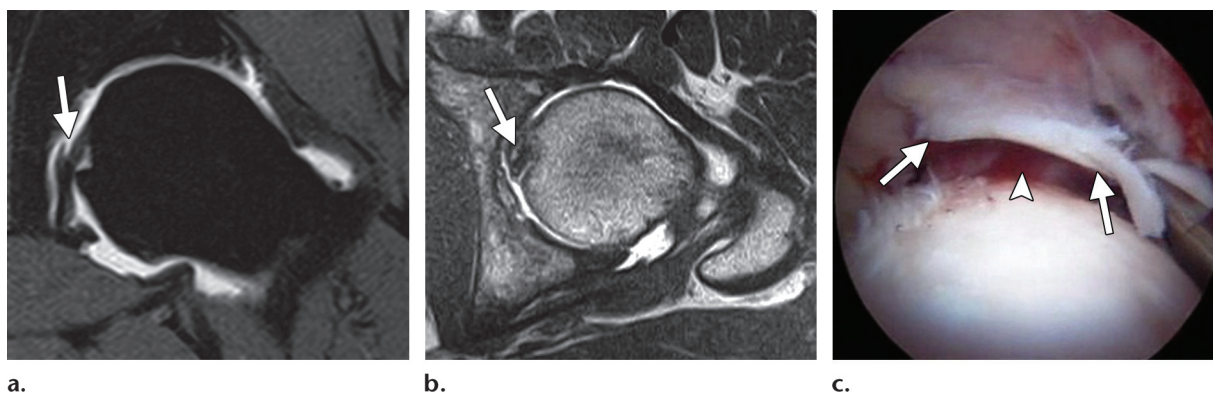


Figure 14. Partial tear of the ligamentum teres. (a, b) Coronal T1-weighted fat-suppressed (a) and axial T1-weighted (b) MR arthrograms obtained in the same patient as Figure 13 show intraarticular extension of contrast material into a partial-thickness tear of the proximal part of the ligamentum teres (arrow). (c) Arthroscopic image shows the partial, superficial flaplike tear (arrows). The rest of the ligamentum teres was intact (arrowhead).

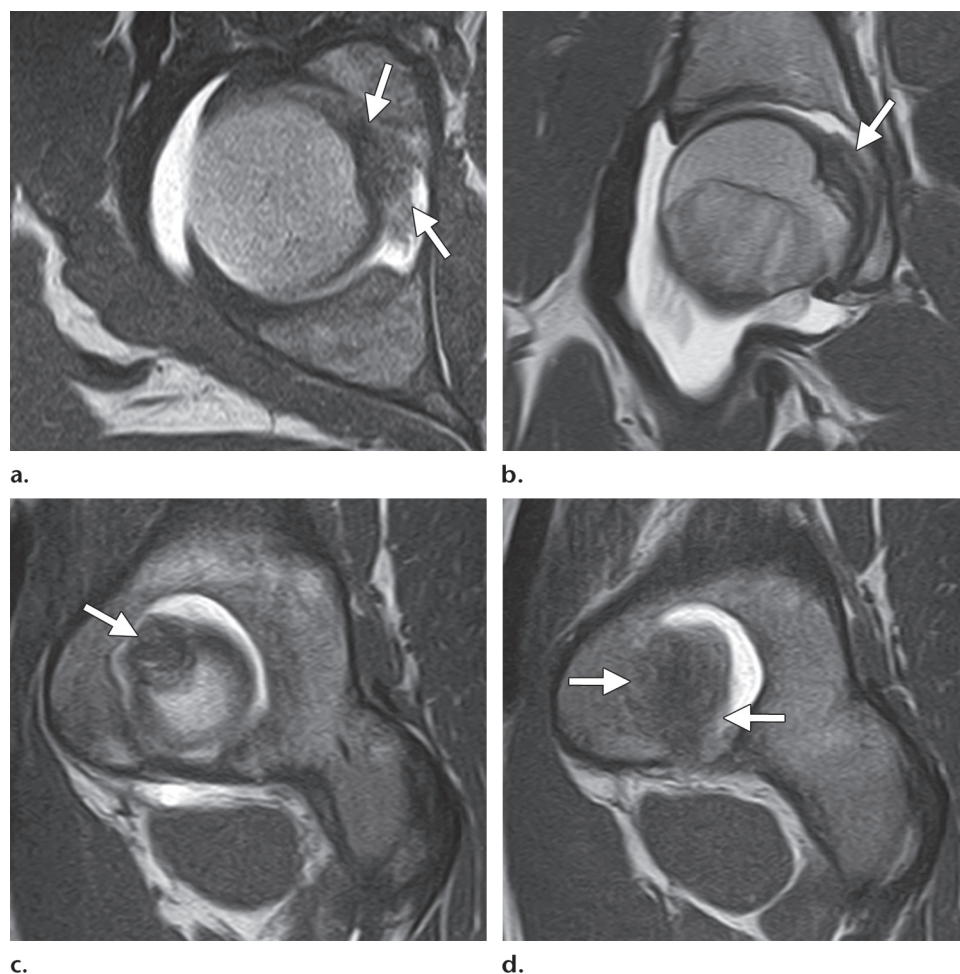


Figure 15. Degeneration of the ligamentum teres. Axial (a), coronal (b), and sagittal (c, d) MR arthrograms show diffuse degenerative thickening of the ligamentum teres (arrows), a finding that is most pronounced proximally. No increased signal intensity is seen. The patient had no history of trauma but reported groin pain and hip locking.

Mucinous or mucoid degeneration represents a response of the ligamentum teres to degeneration or chronic tears. Mucinous or mucoid

degeneration usually is associated with other degenerative intraarticular joint conditions such as cartilage injuries and secondary subchondral changes (eg, cysts and sclerosis). MR imaging and MR arthrographic findings of mucoid degen-

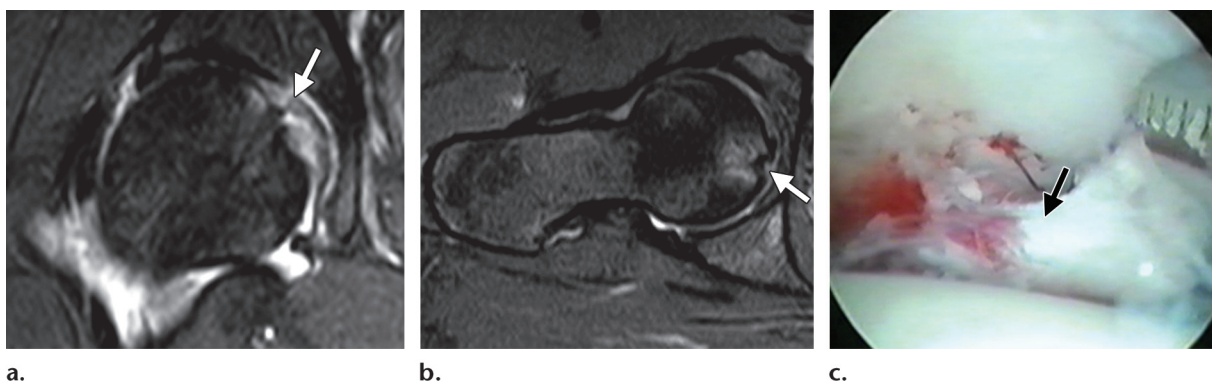
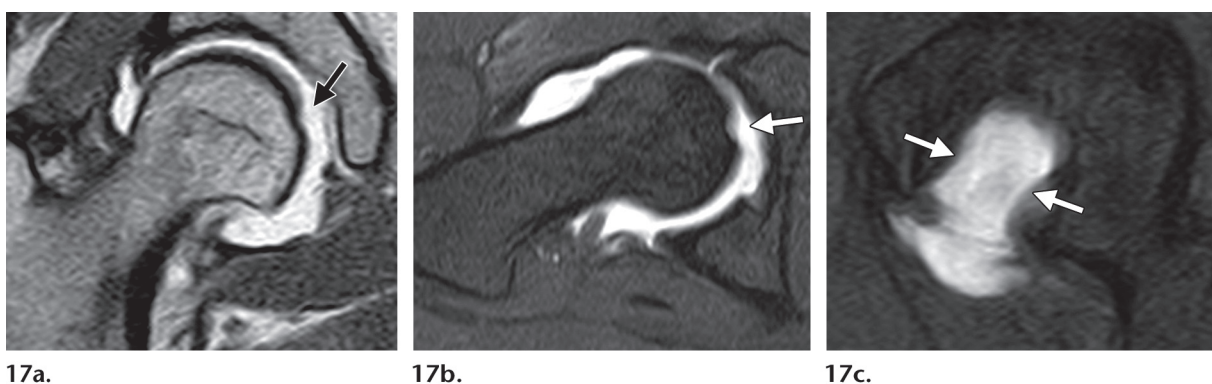
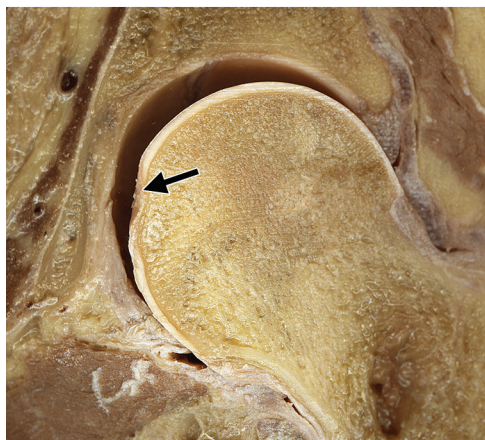
Figure 16. Acute avulsion fracture of the ligamentum teres. **(a, b)** Coronal **(a)** and axial oblique **(b)** T2-weighted fat-suppressed MR images show an acute avulsion fracture of the foveal attachment of the ligamentum teres (arrow) and mild associated marrow edema. **(c)** Arthroscopic image shows a displaced avulsion fracture (arrow) at the foveal insertion of the ligamentum teres.



Figures 17, 18. **(17)** Congenital absence of the ligamentum teres in a patient with DDH. Coronal **(a)**, axial oblique fat-suppressed **(b)**, and sagittal fat-suppressed **(c)** T1-weighted MR arthrograms show a complete absence of the ligamentum teres (arrows) and excessive joint distraction, a finding indicative of moderate instability. **(18)** Photograph of a coronal cadaveric section shows a complete absence of the ligamentum teres and a hypoplastic fovea capitis femoris (arrow).



18.

erative changes include increased signal intensity of the ligamentum teres on T1- and T2-weighted sequences. Often these degenerative changes are associated with irregular ligament contours and focal areas of partial, or, less commonly, complete loss of continuity. These changes are best depicted at CT or MR arthrography; however, it may be difficult to differentiate a degenerative tear from a traumatic tear (Fig 15). In such cases, correlation with the patient's clinical history helps determine the cause.

Avulsion fractures of the foveal attachment of the ligamentum teres may be nondisplaced, par-

tially displaced, or completely displaced. Completely displaced avulsion fractures of the ligamentum teres may be clearly seen at MR arthrography; however, partial or nondisplaced avulsion fractures may be overlooked. In these cases, careful evaluation of the signal intensity of marrow on T2-weighted or proton-density fat-suppressed images is essential (Fig 16). CT arthrography allows for better assessment of nondisplaced fracture fragments than MR arthrography.

Congenital absence of the ligamentum teres is rare, and its existence is still under debate in the literature. It is difficult to differentiate between congenital absence and a chronic complete tear of the ligamentum teres. Complete absence of the ligamentum teres and a shallow fovea are indicative of congenital absence (Figs 17, 18).

Treatment: Current and Future

Currently, ligamentum teres lesions are treated arthroscopically (11,37–39). Although the indications for treatment are evolving, common indications include pain or mechanical symptoms associated with MR imaging findings of ligamentous hypertrophy, tearing (partial or complete), or edema in the acetabular fossa (8,38). Although it is uncommon, avulsion fracture of the ligamentum teres with intraarticular osteochondral fragments is another indication for surgery (40). Prolonged unexplained hip pain with negative imaging results and relief of symptoms after injection of anesthetics into the hip is another indication for arthroscopy, although it is not necessarily associated with a torn ligamentum teres.

Treatment options for ligamentum teres lesions currently are limited to débridement and shrinkage. Débridement of frayed and torn ligamentum teres fibers—or the stump in the case of complete tears—relieves mechanical symptoms and pain (8,38,39). It is easiest to perform with the hip in external rotation because this position moves the ligament anteriorly and allows improved visualization and access to the area being treated. In the case of partial tears, if shrinkage (with a radiofrequency ablation probe) is to be performed, it is important that the hip be in a neutral position and that careful attention to detail is paid because over-shrinkage may result in limitation of external hip rotation. After shrinkage, a fibroplastic response may increase or improve the biomechanical strength of the remaining fibers of the ligamentum teres.

Although isolated tears of the ligamentum teres may occur, most tears are associated with other intraarticular conditions such as labral tears and cartilage lesions (8,25). Complete tears of the ligamentum teres typically carry a much more guarded prognosis because the original injury, which often is severe, predisposes the hip to development of degenerative arthritis. Interestingly, this predisposition also applies to hips with a complete tear of the ligament but no macroscopic (visible) damage to other structures.

In patients with a complete tear and a stump with an attached bone fragment, arthroscopic débridement has good results, particularly if no associated acetabular fracture or femoral or acetabular osteochondral defect is present (7,40). As was previously noted, patients with a complete

ligamentum teres tear have a guarded prognosis because of the high incidence of premature degenerative arthritis among these patients, which presumably is a result of the original injury.

Reports of ligamentum teres reconstruction are limited; there is only one anecdotal report of reconstruction with a fascia lata autograft. Given the relatively rapid progression of ACL reconstructions and the proposed similarities between the ACL and the ligamentum teres, it is possible that open or arthroscopic ligamentum teres reconstruction may be a common procedure in the near future.

More studies with larger series and longer follow-up are needed to better understand the anatomy, biomechanics, and mechanisms of injury, as well as the role of imaging in decision making and the role of débridement in the setting of ligamentum teres injuries. However, given its similarities with the ACL, there is optimism about the future of ligamentum teres reconstruction.

Conclusions

Lesions of the ligamentum teres are an increasingly recognized cause of persistent hip pain and should be considered in the differential diagnosis even when imaging results are negative. Conventional (nonarthrographic) CT and MR imaging appear to have a limited role in the evaluation of ligamentum teres injuries. CT and MR arthrography have emerged as the modalities of choice for preoperative imaging of these injuries. To date, preoperative detection of ligamentum teres tears has been disappointing, but with appropriate imaging and a high level of suspicion, preoperative detection of these injuries should improve.

References

1. Rao J, Zhou YX, Villar RN. Injury to the ligamentum teres: mechanism, findings, and results of treatment. *Clin Sports Med* 2001;20(4):791–799, vii.
2. Bardakos NV, Villar RN. The ligamentum teres of the adult hip. *J Bone Joint Surg Br* 2009;91(1):8–15.
3. Barrett IR, Goldberg JA. Avulsion fracture of the ligamentum teres in a child: a case report. *J Bone Joint Surg Am* 1989;71(3):438–439.
4. Byrd JW, Jones KS. Traumatic rupture of the ligamentum teres as a source of hip pain. *Arthroscopy* 2004;20(4):385–391.
5. Delcamp DD, Klaaren HE, Pompe van Meerdervoort HF. Traumatic avulsion of the ligamentum teres without dislocation of the hip: two case reports. *J Bone Joint Surg Am* 1988;70(6):933–935.
6. Gray AJ, Villar RN. The ligamentum teres of the hip: an arthroscopic classification of its pathology. *Arthroscopy* 1997;13(5):575–578.

7. Kusma M, Jung J, Dienst M, Goedde S, Kohn D, Seil R. Arthroscopic treatment of an avulsion fracture of the ligamentum teres of the hip in an 18-year-old horse rider. *Arthroscopy* 2004;20(suppl 2):64–66.
8. Philippon MJ, Kuppersmith DA, Wolff AB, Briggs KK. Arthroscopic findings following traumatic hip dislocation in 14 professional athletes. *Arthroscopy* 2009;25(2):169–174.
9. Sampatchalit S, Barbosa D, Gentili A, Haghighi P, Trudell D, Resnick D. Degenerative changes in the ligamentum teres of the hip: cadaveric study with magnetic resonance arthrography, anatomical inspection, and histologic examination. *J Comput Assist Tomogr* 2009;33(6):927–933.
10. Wettstein M, Garofalo R, Borens O, Mouhsine E. Traumatic rupture of the ligamentum teres as a source of hip pain. *Arthroscopy* 2005;21(3):382; author reply 383.
11. Yamamoto Y, Usui I. Arthroscopic surgery for degenerative rupture of the ligamentum teres femoris. *Arthroscopy* 2006;22(6):689.e1–689.e3.
12. Yamamoto Y, Villar RN, Papavasiliou A. Supermarket hip: an unusual cause of injury to the hip joint. *Arthroscopy* 2008;24(4):490–493.
13. Armfield DR, Towers JD, Robertson DD. Radiographic and MR imaging of the athletic hip. *Clin Sports Med* 2006;25(2):211–239, viii.
14. Blankenbaker DG, Tuite MJ. The painful hip: new concepts. *Skeletal Radiol* 2006;35(6):352–370.
15. Byrd JW, Jones KS. Diagnostic accuracy of clinical assessment, magnetic resonance imaging, magnetic resonance arthrography, and intra-articular injection in hip arthroscopy patients. *Am J Sports Med* 2004;32(7):1668–1674.
16. Erb RE. Current concepts in imaging the adult hip. *Clin Sports Med* 2001;20(4):661–696.
17. Schneider G, Massmann A, Fries P, Kusma M, Dienst M. Magnetic resonance tomography and arthrography of the hip joint [in German]. *Orthopade* 2006;35(1):22–26, 28–32.
18. Demange MK, Kakuda CM, Pereira CA, Sakaki MH, Albuquerque RF. Influence of the femoral head ligament on hip mechanical function. *Acta Orthop Bras* 2007;15(4):187–190.
19. Chen HH, Li AF, Li KC, Wu JJ, Chen TS, Lee MC. Adaptations of ligamentum teres in ischemic necrosis of human femoral head. *Clin Orthop Relat Res* 1996 (328):268–275.
20. Oda H, Igarashi M, Hayashi Y, et al. Soft tissue collagen in congenital dislocation of the hip: biochemical studies of the ligamentum teres of the femur and the hip joint capsule. *Nippon Seikeigeka Gakkai Zasshi* 1984;58(3):331–338.
21. Chandler SB, Kreuzer PH. A study of the blood supply of the ligamentum teres and its relation to the circulation of the head of the femur. *J Bone Joint Surg Am* 1932;14:834–846.
22. Weathersby HT. The origin of the artery of the ligamentum teres femoris. *J Bone Joint Surg Am* 1959;41-A(2):261–263.
23. Hankenson KD, Turek JJ. Porcine anterior cruciate ligament fibroblasts are similar to cells derived from the ligamentum teres, another non-healing intra-articular ligament. *Connect Tissue Res* 1999;40(1):13–21.
24. Wenger D, Miyajiri F, Mahar A, Oka R. The mechanical properties of the ligamentum teres: a pilot study to assess its potential for improving stability in children's hip surgery. *J Pediatr Orthop* 2007;27(4):408–410.
25. Guanche CA, Sikka RS. Acetabular labral tears with underlying chondromalacia: a possible association with high-level running. *Arthroscopy* 2005;21(5):580–585.
26. Sarban S, Baba F, Kocabey Y, Cengiz M, Isikan UE. Free nerve endings and morphological features of the ligamentum capitis femoris in developmental dysplasia of the hip. *J Pediatr Orthop B* 2007;16(5):351–356.
27. Leunig M, Beck M, Stauffer E, Hertel R, Ganz R. Free nerve endings in the ligamentum capitis femoris. *Acta Orthop Scand* 2000;71(5):452–454.
28. Kawaguchi AT, Otsuka NY, Delgado ED, Genant HK, Lang P. Magnetic resonance arthrography in children with developmental hip dysplasia. *Clin Orthop Relat Res* 2000 (374):235–246.
29. Roy DR. Arthroscopy of the hip in children and adolescents. *J Child Orthop* 2009;3(2):89–100.
30. Gillet P, Péré P, Jouzeau JY, Floquet J, Gaucher A. Enthesitis of the ligamentum teres during ankylosing spondylitis: histopathological report. *Ann Rheum Dis* 1994;53(1):82.
31. Inoue K, Schichikawa K, Takenaka Y, Yamauchi E, Nishioka J, Hukuda S. Ossification of the ligamentum teres as a possible mechanism of lateral subluxation in coxopathy associated with ankylosing spinal hyperostosis. *Ann Rheum Dis* 1993;52(4):306–307.
32. De Lee JC. Fractures and dislocations of the hip. In: Rockwood CA, Green DP, Heckman JD, et al, eds. *Fractures in adults*. 4th ed. Vol 2. Philadelphia, Pa: Lippincott, 1996; 1756–1803.
33. Ebraheim NA, Savolaine ER, Fenton PJ, Jackson WT. A calcified ligamentum teres mimicking entrapped intraarticular bony fragments in a patient with acetabular fracture. *J Orthop Trauma* 1991;5(3):376–378.
34. Remes V, Tervahartia P, Helenius I, Peltonen J. Magnetic resonance imaging analysis of hip joint development in patients with diastrophic dysplasia. *J Pediatr Orthop* 2002;22(2):212–216.
35. Tibor LM, Sekiya JK. Differential diagnosis of pain around the hip joint. *Arthroscopy* 2008;24(12):1407–1421.
36. Llopis E, Cerezal L, Kassarian A, Higuera V, Fernandez E. Direct MR arthrography of the hip with leg traction: feasibility for assessing articular cartilage. *AJR Am J Roentgenol* 2008;190(4):1124–1128.
37. Philippon MJ, Schenker ML, Briggs KK, Kuppersmith DA, Maxwell RB, Stubbs AJ. Revision hip arthroscopy. *Am J Sports Med* 2007;35(11):1918–1921.
38. Kelly BT, Buly RL. Hip arthroscopy update. *HSS J* 2005;1(1):40–48.
39. Bharam S. Labral tears, extra-articular injuries, and hip arthroscopy in the athlete. *Clin Sports Med* 2006;25(2):279–292, ix.
40. Kashiwagi N, Suzuki S, Seto Y. Arthroscopic treatment for traumatic hip dislocation with avulsion fracture of the ligamentum teres. *Arthroscopy* 2001;17(1):67–69.

Anatomy, Biomechanics, Imaging, and Management of Ligamentum Teres Injuries

Luis Cerezal, MD, et al

RadioGraphics 2010; 30:1637–1651 • Published online 10.1148/rg.306105516 • Content Code: **MK**

Page 1638

The ligamentum teres predominantly arises from the transverse acetabular ligament along the inferior margin of the acetabulum. It is attached to the periosteum by two bands (fascicles), which are located along the ischial and pubic margins of the acetabular notch.

Page 1641

At CT and MR imaging, the ligamentum teres has a smooth contour and a relatively homogeneous structure, and at MR imaging it is hypointense on all pulse sequences, although areas of slightly increased signal intensity may be seen near its attachment to the fovea capitis femoris, a finding that may be due to the “magic angle” artifact.

Page 1643

First, the ligamentum teres may be to the hip what the anterior cruciate ligament (ACL) is to the knee: a strong intrinsic stabilizer that resists joint subluxation forces.

Page 1644

Although a torn ligamentum teres typically is associated with hip dislocation, partial or complete tears may occur in the setting of other joint stresses such as a flexion-adduction stress, which occurs when a patient falls on the ipsilateral knee with the hip flexed, or a sudden twisting injury (usually external rotation) of the hip.

Page 1646

Because partial and complete tears of the ligamentum teres are most common near the fovea capitis femoris, close attention should be paid to this region when evaluating MR, MR arthrographic, and CT arthrographic images of the hip.